



## Review

# X-linked adrenoleukodystrophy: Clinical, metabolic, genetic and pathophysiological aspects <sup>☆</sup>

Stephan Kemp <sup>a,b,\*</sup>, Johannes Berger <sup>c</sup>, Patrick Aubourg <sup>d,e</sup>

<sup>a</sup> Department of Clinical Chemistry, Laboratory Genetic Metabolic Diseases, Academic Medical Center, University of Amsterdam, The Netherlands

<sup>b</sup> Department of Pediatric Neurology/Emma Children's Hospital, Academic Medical Center, University of Amsterdam, The Netherlands

<sup>c</sup> Center for Brain Research, Medical University of Vienna, Vienna, Austria

<sup>d</sup> Assistance Publique des Hôpitaux de Paris, Department of Pediatric Neurology, Hospital Kremlin-Bicêtre, France

<sup>e</sup> INSERM UMR745, University Paris-Descartes, Paris, France

## ARTICLE INFO

## Article history:

Received 17 October 2011

Received in revised form 8 March 2012

Accepted 20 March 2012

Available online 28 March 2012

## Keywords:

ALDP

ELOVL1

Peroxisome

VLCFA

Leukodystrophy

ABCD1

## ABSTRACT

X-linked adrenoleukodystrophy (X-ALD) is the most frequent peroxisomal disease. The two main clinical phenotypes of X-ALD are adrenomyeloneuropathy (AMN) and inflammatory cerebral ALD that manifests either in children or more rarely in adults. About 65% of heterozygote females develop symptoms by the age of 60 years. Mutations in the *ABCD1* gene affect the function of the encoded protein ALDP, an ATP-binding-cassette (ABC) transporter located in the peroxisomal membrane protein. ALDP deficiency impairs the peroxisomal beta-oxidation of very long-chain fatty acids (VLCFA) and facilitates their further chain elongation by ELOVL1 resulting in accumulation of VLCFA in plasma and tissues. While all patients have mutations in the *ABCD1* gene, there is no general genotype–phenotype correlation. Environmental factors and a multitude of modifying genes appear to determine the clinical manifestation in this monogenetic but multifactorial disease. This review focuses on the clinical, biochemical, genetic and pathophysiological aspects of X-ALD. This article is part of a Special Issue entitled: Metabolic Functions and Biogenesis of Peroxisomes in Health and Disease.

© 2012 Elsevier B.V. All rights reserved.

## 1. Clinical aspects of X-ALD

X-linked adrenoleukodystrophy (X-ALD) is clinically characterized by two main phenotypes: adrenomyeloneuropathy (AMN) and the cerebral demyelinating form of X-ALD (cerebral ALD) [1,2]. AMN and cerebral ALD occur frequently within the same family and there is no correlation between X-ALD phenotype and mutations in the *ABCD1* gene (see below). Cerebral ALD presents usually with a rapidly progressive inflammatory demyelination within the brain resulting in severe cognitive and neurologic disability, a vegetative state within two to five years of clinical symptom onset and death thereafter. This phenotype is most common during childhood (childhood cerebral ALD; CCALD) and adolescence (adolescent cerebral ALD), but up to 20% of adult males initially presenting with AMN will develop cerebral ALD later in life [3]. The pathology of AMN is fundamentally different from that of cerebral ALD and is characterized predominantly by a noninflammatory distal axonopathy involving mostly the long tracts of the spinal cord that results in a progressive spastic paraplegia [1,2].

### 1.1. Adrenomyeloneuropathy (AMN) in males and heterozygous women

AMN is the most frequent phenotype of X-ALD [1,2]. A newborn male with X-ALD, as identified by a mutation in the *ABCD1* gene, is likely to develop AMN in adulthood. The first symptoms of AMN usually appear when male patients are between 20 and 30 years but usually before the fifth decade [3]. Initially, the neurologic disability is slowly progressive. The diagnosis of AMN is rarely made during the first 3–5 years of clinical symptoms, unless other cases of X-ALD have been identified in the same family. AMN males develop progressive stiffness and weakness of the legs, impaired vibration sense in the lower limbs, sphincter disturbances and impotence. Although nerve conduction studies suggest very frequently the presence of axonal and/or demyelinating neuropathy in AMN males, the clinical burden of peripheral nerve involvement is often difficult to assess because of prominent spinal cord symptoms [4]. Adult males with AMN frequently have scanty scalp hair that often develops during adolescence.

In an earlier study, half of heterozygous women were shown to have AMN symptoms [5]. An increased number of heterozygous women with AMN symptoms are now being identified as the first member of their family to be affected by X-ALD and the real incidence of AMN in heterozygous women is likely to be close to 65% by the age of 60 years (Engelen et al., manuscript in preparation). In general, the onset of neurologic symptoms occurs at a later age than in males with

<sup>☆</sup> This article is part of a Special Issue entitled: Metabolic Functions and Biogenesis of Peroxisomes in Health and Disease.

\* Corresponding author. Tel.: +31 20 5665958; fax: +31 20 6962596.

E-mail address: [s.kemp@amc.uva.nl](mailto:s.kemp@amc.uva.nl) (S. Kemp).

AMN; typically in the fourth to fifth decade of life. Motor disability and disease progression are generally less severe but some heterozygous women are as severely impaired as male patients with X-ALD. Peripheral nerve involvement is observed less frequently. Scanty scalp hair can also be found in heterozygotes.

The evolution of AMN in adult males and heterozygous women is quite variable; a relapsing and remitting evolution is never seen. In two-thirds of AMN patients, the neurologic disability progresses slowly. Within 10–15 years, motor disability becomes severe and requires the use of a cane or a wheelchair. However, 35% of patients with AMN have a marked progression of their myelopathy within the first 3–5 years of clinical symptom onset. Adrenocortical insufficiency (Addison's disease) is present in approximately two-thirds of males with AMN but is often latent without evident clinical manifestations, including melanoderma. Addison's disease is present in less than 1% of heterozygous women. Of note, however, the clinical diagnosis of Addison's disease can be made in males with X-ALD, years or even decades before the onset of neurological AMN symptoms.

A moderate increase of the brain MRI signal of the white matter in the centrum ovale on FLAIR sequences is frequently seen several years after onset of symptoms. Furthermore, there can be abnormal hypersignal of the pyramidal tracts in brainstem and internal capsules on FLAIR and T2 sequences. There is no cerebral demyelination based on abnormal hypersignal on FLAIR and T2 sequences in the parieto-occipital or frontal white matter MRI of the brain [3,6]. Cerebellar atrophy with or without demyelination of the cerebellar white matter may also appear. As the disease progresses, MR spectroscopy shows in the cerebral white matter a decrease of N-acetyl-aspartate (NAA)/creatinine ratio reflecting axonal loss and an increase of choline/creatinine and myo-inositol/creatinine ratios reflecting lipid turn-over changes [7]. MRI of the spinal cord shows non-specific atrophy but without gadolinium enhancement as it can be observed in multiple sclerosis. More sophisticated MR techniques such as magnetization transfer or diffusion tensor-based imaging may however show abnormalities in the lateral and dorsal columns of the spinal cord and in the cortico-spinal tracts from spinal cord to brain [8–10].

Evoked potentials show delayed responses, first of brainstem evoked responses, then of motor evoked responses of lower limbs, and last of somatosensory-evoked responses of the lower limbs [11]. Visual evoked responses are usually normal or show moderate increase of P100 latency. Electromyography and nerve conduction velocities demonstrate the presence of axonal and/or demyelinating polyneuropathy in the lower limbs of 75% of AMN males and 40% of women with AMN [4]. The differential diagnosis of AMN includes other hereditary forms of spastic paraplegia and the primary progressive form of multiple sclerosis.

Twenty percent of AMN males develop, usually between 20 and 35 years of age, a cerebral demyelinating form of the disease [3]. This risk decreases markedly after the age of 45 years. The progression of demyelinating lesions is initially slower than in boys with cerebral ALD. After several months or years of progression, cerebral ALD may even arrest, but once the cerebral demyelinating lesions become inflammatory with evidence of enhanced contrast of the demyelinating lesions after intravenous injection of gadolinium, cerebral ALD in adult males has the same poor prognosis as in boys with inflammatory cerebral ALD. The occurrence of cerebral ALD in females is exceptional.

### 1.2. The cerebral demyelinating form of X-ALD

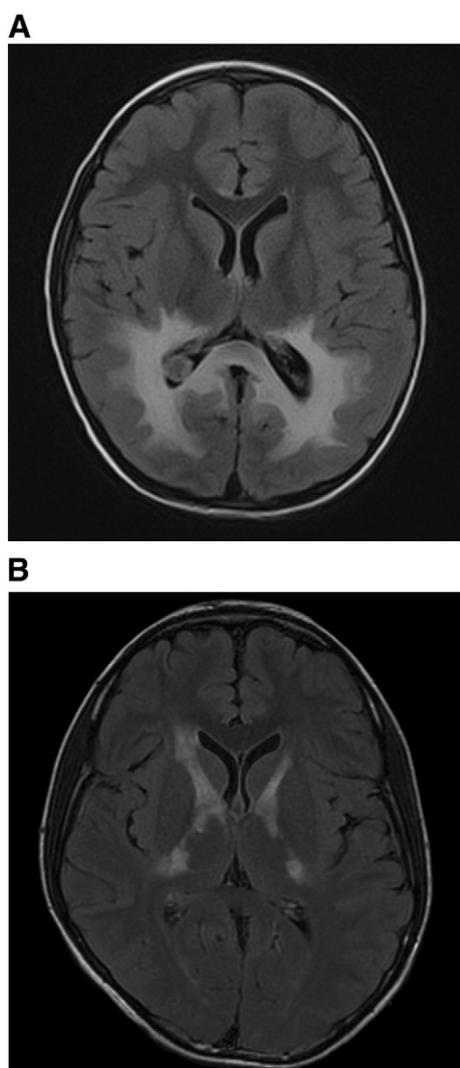
Cerebral ALD is the most severe phenotype of X-ALD. A newborn male with an *ABCD1* gene mutation has a 35–40% risk to develop cerebral ALD between the ages of 5 and 12 years. As mentioned above, 20% of adult AMN males are also at risk to develop cerebral ALD. Overall, for male X-ALD patients the lifetime risk to develop cerebral ALD, either in childhood or in adulthood, is around 60%. There is an age-

related correlation with the onset of cerebral ALD and disease progression: the earlier the onset of cerebral demyelination, the more rapid the progression of the disease. Patients are neurologically unaffected until they develop cerebral demyelination visible on brain MRI (as abnormal hypersignal of white matter on T2 and FLAIR sequences, hyposignal of white matter on T1 sequences) [1,12,13]. Usually the initial lesions involve either the splenium of the corpus callosum and then extend into the adjacent white matter of the parieto-occipital lobes (Fig. 1A) or alternatively the genu of the corpus callosum and then extend into the white matter of the frontal lobes. Initial demyelinating lesions may also occur in the pyramidal tracts, within the brainstem or internal capsule (Fig. 1B) and then extend into the centrum semiovale (frontal white matter). The cerebral demyelinating lesions can be asymmetric, particularly when previous head trauma or even stroke seems to have initiated the onset of cerebral ALD. Initially, the demyelinating lesions are not inflammatory (based on absence of lesion enhancement on T1 sequences after peripheral injection of gadolinium) and progress slowly. The patients have virtually no neurologic symptoms, except sometimes mild cognitive dysfunctions. Suddenly, the disease becomes inflammatory (with evidence of demyelinating lesion enhancement after peripheral injection of gadolinium) and at this stage the disease starts to progress rapidly. The patients enter then into an active phase of devastating neurologic and cognitive deterioration that includes emotional lability, hyperactive behavior, school failure for boys, and either visuo-spatial impairment or frontal syndrome according to the sites of cerebral demyelinating lesions. This cognitive deterioration is rapidly associated with neurologic deficits such as hemiplegia or quadriplegia, cerebellar ataxia, impaired central auditory discrimination, visual field defects, cortical blindness and often seizures. Eventually, a vegetative state ensues within two to five years leading to death at varying intervals thereafter. Approximately 65% of children or adults with cerebral ALD have adrenocortical insufficiency that can precede the onset of neurologic symptoms for years or decades.

About 10% of boys with cerebral ALD may not enter into the active inflammatory and devastating stage of the disease. The same may occur in adult males with cerebral ALD. This phenotype is often referred to as “chronic or arrested cerebral X-ALD”. With white matter lesions involving either the parieto-occipital or the frontal white matter, these patients end up developing marked visual-spatial or executive cognitive deficits, but without significant neurological or sensory (visual, auditory) symptoms. After an initial progression of the demyelinating lesions that often result in loss of myelin and ventricular dilatation and cortical atrophy, the patient can remain stable for a decade or even longer. But a full progression to the inflammatory stage remains possible, even after 10 to 15 years without progression of cerebral demyelination. Electrophysiological tests are useless for the early diagnosis of cerebral ALD as brainstem visual evoked responses become abnormal only in the advanced stage of the disease. The occurrence of childhood cerebral ALD in females is exceptional. It is hypothesized and partially supported by laboratory studies that the few girls who developed CCALD had skewed X-inactivation toward the X-chromosome carrying the mutated *ABCD1* gene (Kemp, unpublished data).

### 1.3. Other X-ALD phenotypes

Rarely, X-ALD males remain completely asymptomatic, even without signs of adrenocortical insufficiency, up to the age of 40–50 years. About one-third of heterozygous women remain free of clinical symptoms during their entire life. Adrenocortical insufficiency may be the first manifestation of X-ALD in boys or adults. About 10% of X-ALD males have only primary adrenocortical insufficiency (Addison's disease) initially without evidence of nervous system involvement at one time of their life (either in childhood or adulthood) [14]. These patients are, however, at risk to develop AMN or cerebral



**Fig. 1.** (A) Brain MRI (axial images; FLAIR sequence) showing abnormally increased signal in the splenium of the corpus callosum, the parieto-occipital white matter, the visual pathways (optic radiations and lateral geniculate bodies), as well as the medial geniculate bodies of auditory pathway and the posterior limbs of the internal capsules. The demyelinating lesions are extensive and correspond to an advanced disease stage. (B) Brain MRI (axial images; FLAIR sequence) showing abnormally increased signal involving the posterior and anterior limbs of the left and right internal capsule.

ALD. The cerebral ALD phenotype is not fully penetrant, but the AMN phenotype is fully penetrant in adults after the age of 55 years. Asymptomatic males with X-ALD after this age are extremely rare. Adult X-ALD males may develop testicular insufficiency due to involvement of Sertoli and Leydig cells that sometimes results in clinical symptoms leading to a diagnosis of X-ALD. However, most of these patients already had clinical signs of AMN at the time they developed testicular insufficiency. Heterozygous women have no endocrine problems, except for the presence of adrenocortical insufficiency in <1% of cases.

## 2. Biochemical aspects

### 2.1. The biochemical defect in X-ALD

By the early 1970s, twelve fully documented clinical reports were available describing boys with adrenocortical atrophy and diffuse cerebral sclerosis in combination with strong evidence of an X-linked recessive mode of inheritance. Biochemical analysis of the brain at autopsy revealed the first clue pointing toward an underlying metabolic cause.

Using thin layer chromatography Forsyth and coworkers demonstrated an increase in esterified cholesterol in the white matter and cortex of the occipital and parietal lobes. Based on this finding the authors proposed X-ALD as an inborn error of metabolism common to the adrenal cortex and the brain [15]. In 1973, Powers and Schaumburg demonstrated unusual striations in the inner adrenocortical cells which were shown to consist of intracytoplasmic lamellae and lamellar lipid inclusions by electron microscopy [16]. Lipid inclusions were also found in testicular cells, Schwann cells and brain macrophages from patients with X-ALD [16]. Johnson and coworkers demonstrated that the striated material from adrenal and cerebral white matter was resistant to acetone and ethanol extraction, but readily soluble in nonpolar solvents such as hexane and chloroform [17]. This suggested the accumulation of an unusually nonpolar material in these tissues. Subsequently, biochemical analysis of the inclusion bodies revealed that they contained cholesterol, phospholipids and gangliosides esterified with saturated very long-chain fatty acids (VLCFA) [18]. These findings defined X-ALD as a lipid-storage disease and led to the hypothesis that aberrant metabolism of the VLCFA is the key factor in the pathogenesis of X-ALD. This hypothesis was confirmed by Singh and coworkers with the demonstration that the oxidation of C24:0 and C26:0 is reduced in fibroblasts from X-ALD patients, whereas oxidation of radiolabeled C16:0 was fully normal in X-ALD cells [19]. Osmundsen demonstrated that hepatocytes of clofibrate-treated rats showed a marked increase in the C22:1 beta-oxidation capacity. This observation prompted the conclusion that VLCFA are oxidized in non-mitochondrial subcellular compartments [20]. Next, Singh and coworkers showed that in rat liver and cultured human skin fibroblasts radiolabeled C24:0 is oxidized mainly and possibly exclusively in peroxisomes and that it is this system that is defective in X-ALD [21]. More recently it has been demonstrated that stable isotope-labeled fatty acids, like D<sub>3</sub>-C22:0 [22] and D<sub>3</sub>-C24:0 [23] can be used as an alternative to 1-[<sup>14</sup>C]-labeled C24:0 for studying fatty acid metabolism. The peroxisomal beta-oxidation activity is calculated from the amounts of D<sub>3</sub>-C16:0 generated intracellularly. In fibroblasts derived from patients with a defect in one of the peroxisomal beta-oxidation enzymes, such as acyl-CoA oxidase (AOX) deficiency and bifunctional protein (DBP) deficiency, no D<sub>3</sub>-C16:0 could be detected [23]. These data confirmed that beta-oxidation of VLCFA takes place exclusively in peroxisomes and not in mitochondria.

The discovery by Moser and coworkers that VLCFA (in particular C26:0) are also elevated in readily accessible materials like blood cells and plasma of X-ALD patients has been of crucial importance for the diagnosis of X-ALD [24]. This finding allowed unequivocal identification of male patients. Today, plasma VLCFA analysis is still the best initial biomarker for the diagnosis of X-ALD. Three parameters are analyzed: the amount of C26:0 and the ratios of C24:0/C22:0 and C26:0/C22:0 [24]. Plasma VLCFA analysis is recommended in all male patients with progressive spastic paraparesis of unknown cause, Addison's disease and those presenting typical pattern of cerebral demyelination at brain MRI. In males, unambiguous diagnosis of X-ALD can be achieved by demonstration of elevated levels of VLCFA in plasma. In women who are heterozygous for X-ALD plasma VLCFA levels often are increased. However, it should be stressed that studies in obligate heterozygotes have shown false negative results in approximately 20% of cases [14]. Thus, a normal plasma VLCFA level does not exclude heterozygosity for X-ALD. Therefore, mutation analysis is the most reliable method for the identification of heterozygotes, provided that the mutation in the family has been defined in an affected male or obligate heterozygote relative [25]. However, it is our experience that more and more symptomatic heterozygous women with AMN are identified as the index patient in a family.

Elevated VLCFA levels are present in many different lipid species in X-ALD patients. The greatest excess has been reported in the ganglioside, phosphatidylcholine, sphingomyelin, cerebroside and sulfatide ester fractions [18,26–29]. VLCFA are not elevated in the phosphatidylinositol ester fraction and the level of nervonic acid C24:1 (n-9) is reduced in the



brain sphingolipids of X-ALD patients [29]. Effects on protein acylation have also been reported. For example, the hydrophobic myelin proteolipid protein (PLP) contains covalently bound long-chain fatty acids (mainly C16:0, C16:1, C18:0 and C18:1) which are attached to intracellular cysteine residues via thioester linkages [30]. In X-ALD there is an increase in the amount of VLCFA bound to PLP [27]. Recently, combined liquid chromatography-tandem mass spectrometry showed that VLCFA are highly enriched in the lysophosphatidylcholine (lysoPC) fraction [31], providing the basis for newborn screening for X-ALD [32].

Reinecke and coworkers combined histopathological and biochemical analyses of the brain and demonstrated that VLCFA accumulate in morphological normal brain indicating that the biochemical abnormality precedes histopathological changes [33]. These data were confirmed by Theda and coworkers who found that in regions in which myelin was intact the phosphatidylcholine fraction showed the highest VLCFA excess (16-fold higher) which led these authors to conclude that the phosphatidylcholine abnormalities in X-ALD may well be a critical factor in the pathogenesis of the disease [28]. In 2005, Asheuer and coworkers demonstrated that brain VLCFA levels in normal appearing white matter correlate with the clinical phenotype [34]. In comparison with age-matched controls, C26:0 levels were increased 3-fold in CCALD patients, and 1.9-fold in AMN patients. Taken together, these results show that the accumulation in brain VLCFA levels precedes histopathological alterations and are an important factor in the development of cerebral disease.

## 2.2. Toxicity of VLCFA

VLCFA are extremely hydrophobic and they have different physiological properties than long-chain fatty acids. The rate of desorption from biological membranes decreases exponentially with increasing chain length. The desorption of C26:0 from a phospholipid bilayer model membrane is 10,000 times slower than that of C16:0 and C18:0 fatty acids [35]. Microcalorimetric studies have shown that inclusion of C26:0 in a model membrane disrupts membrane structure [35]. This is in agreement with an earlier report that demonstrated an increased membrane microviscosity in erythrocytes isolated from patients with X-ALD [36]. Whitcomb and coworkers provided a more physiological demonstration that VLCFA affect membrane function by assessing the effect of VLCFA on ACTH-stimulated cortisol release in cultured human adrenocortical cells [37]. The addition of VLCFA to the culture medium in concentrations equivalent to those in X-ALD plasma led to an increased microviscosity of adrenocortical cell membranes and a decreased ACTH-stimulated cortisol secretion. The authors concluded that the VLCFA excess altered the membrane structure and suppressed the availability of the ACTH receptor.

Hein and coworkers provided some insight into the cytotoxic effect of VLCFA on neural cells by studying the physiological consequences of VLCFA addition to cultures of oligodendrocytes, astrocytes and neurons that were isolated from rat brain [38]. Exposure of oligodendrocytes and astrocytes to 20  $\mu$ M C22:0, C24:0 and C26:0 caused cell death within 24 h. In contrast, cell death was not seen when the cells were challenged with up to 100  $\mu$ M C16:0. Challenging neural cells with VLCFA induced depolarization of mitochondria *in situ* and induced deregulation of intracellular calcium homeostasis. Interestingly, VLCFA were most toxic to the myelin-producing oligodendrocytes [38]. The authors did not find any evidence for the formation of reactive oxygen species (ROS). Based on the results obtained the authors concluded that VLCFA cause cell death by a combination of a disturbance in calcium homeostasis and mitochondrial dysfunction, but not primarily via ROS-production. It should be noted, however, that based on these results the involvement of ROS in X-ALD pathogenesis can not be excluded because: 1) the cells were exposed to VLCFA for a short time period, and 2) the cells used were derived from wild type rats. Fourcade and coworkers presented evidence of oxidative damage to proteins in

the spinal cord of *ABCD1* knockout mice at the age of 3.5 months [39]. This is long before the first neuropathological lesions in the spinal cord become apparent at around 16 months of age and the onset of clinical signs at 20 months of age [39,40]. Eichler and coworkers addressed the *in vivo* cytotoxic effect of VLCFA complexed to phospholipids by injecting lysophosphatidylcholine containing C24:0 (C24:0-lysoPC) to the cortex of wild type mice [41]. This resulted in microglial activation and apoptosis. Interestingly, C16:0-lysoPC injections did not cause these effects. This indicates a fatty acyl chain length dependent cytotoxicity and suggests that microglial apoptosis caused by toxic levels of VLCFA containing lysoPC may constitute an early pathogenic change in cerebral X-ALD.

## 2.3. VLCFA metabolism

Free fatty acids are in general metabolically inactive. They must be activated by thioesterification to their coenzyme-A form in order to become metabolically active. Based on the initial demonstration by Hashmi and coworkers that the activation of VLCFA to their respective CoA-esters is deficient in X-ALD fibroblasts [42], it was anticipated that ALDP would have VLCFacyl-CoA synthetase activity. It therefore came as a surprise that when the *ABCD1* gene was identified, its product (ALDP) was not a VLCFacyl-CoA synthetase, but a peroxisomal membrane protein belonging to the ATP-binding cassette (ABC) superfamily of transporters [43]. It has now been demonstrated that the fatty acyl transport protein 4 (FATP4) encoded by the *SLC27A4* gene is the fatty acyl-CoA synthetase that preferentially activates VLCFA to their CoA derivatives [44]. Compared to control cells, fibroblasts derived from FATP4-deficient mice had an 83% decrease in C24:0 activation. The peroxisomal C24:0 beta-oxidation capacity was reduced by 58% in FATP4<sup>-/-</sup> cells, and the rates of incorporation of C24:0 into several lipids, including triacylglycerol, cholesterol esters, and major phospholipid species, was reduced by more than 50% [44]. FATP4 is present at multiple subcellular locations which include peroxisomes, mitochondria and endoplasmic reticulum. Thus, FATP4 appears to provide activated VLCFA for most major lipid catabolic and anabolic pathways.

The peroxisomal beta-oxidation machinery required for the oxidation of C26:0-CoA is completely normal in X-ALD patients. Based on complementation studies demonstrating that expression of normal *ABCD1* cDNA in X-ALD patient fibroblasts restored VLCFA beta-oxidation [45] and reduced VLCFA to normal levels [46], it has long been hypothesized that ALDP transports VLCFA across the peroxisomal membrane. Yeast has proved to be a valuable model system in the search for the function of ALDP. Disruption of either Pxa1p or Pxa2p, which are the yeast orthologs of the human ABCD proteins, results in the deficient peroxisomal beta-oxidation [47]. The Pxa1p/Pxa2p heterodimer is involved in the transport of a spectrum of acyl-CoA esters across the peroxisomal membrane [48,49]. Expression of ALDP in the *pxa1/pxa2Δ* double mutant partially rescued the mutant phenotype which implies the involvement of ALDP in the transport of acyl-CoA esters across the peroxisomal membrane [49]. Subsequent studies using human X-ALD fibroblasts by Ofman and coworkers showed that a deficiency in ALDP indeed results in a strong elevation in the levels of C24:0-CoA and C26:0-CoA esters confirming a VLCFacyl-CoA transport deficiency in X-ALD [50]. These data establish that ALDP transports VLCFacyl-CoA into peroxisomes and that ALDP deficiency in X-ALD has two major effects: 1) it impairs peroxisomal VLCFA beta-oxidation and 2) it raises cytosolic VLCFacyl-CoA levels [50]. The elevated levels of VLCFacyl-CoA esters in the cytosol are substrate for further elongation to even longer fatty acids by ELOVL1, the human C26-specific elongase [50,51].

## 2.4. Origin of VLCFA

The VLCFA that accumulate in X-ALD are only partly absorbed from the diet [52]. Tsuji et al. demonstrated that the majority results from endogenous synthesis through elongation of long-chain fatty

acids [53]. This is in line with data by Rizzo et al. who found no differences in C26:0 levels of X-ALD fibroblasts cultured in lipid-free media or under standard tissue culture conditions [54]. In addition, dietary restriction of VLCFA did not lower plasma C26:0 levels in patients with X-ALD [55]. As a result of the impaired VLCFA degradation due to the deficient import of VLCFA-CoA into peroxisomes, the synthesis of VLCFA is enhanced in X-ALD [56].

Fatty acids up to 16 carbon atoms in length are synthesized in the cytosol by the multifunctional protein fatty acid synthase (FAS) which utilizes acetyl-CoA, malonyl-CoA and NADPH to elongate fatty acids in two-carbon increments [57]. The synthesis of saturated VLCFA, mono-unsaturated VLCFA (MUFA) and polyunsaturated fatty acids (PUFA) takes place at the endoplasmic membrane [58] by four distinct enzymes; elongation of very long chain fatty acids (ELOVL), 3-ketoacyl-CoA reductase (HSD17B12), 3-hydroxyacyl dehydratase (HACD3) and trans-2,3-enoyl-CoA reductase (TECR). The initial condensation reaction that is catalyzed by the enzyme ELOVL is considered to be rate limiting [59]. While seven different ELOVL enzymes have been identified in mammals (designated ELOVL1–7) only a single enzyme has been identified so far for the subsequent reaction step [60]. Thus, substrate specificity for the elongation reaction is conferred by ELOVL. ELOVL1, ELOVL3, ELOVL4 and ELOVL6 are involved in the synthesis of saturated and monounsaturated fatty acids and ELOVL2, ELOVL4, ELOVL5 and ELOVL7 are essential for PUFA metabolism. It was recently demonstrated that the synthesis of C24:0 and C26:0 is carried out by the concerted action of ELOVL6 (C18:0–C22:0) and ELOVL1 (C24:0–C26:0) [50] (Fig. 2). Importantly, ELOVL1 knockdown reduces elongation of C22:0 to C26:0 and lowers C26:0 levels in X-ALD fibroblasts [50]. Further research is now warranted to investigate ELOVL1's therapeutic potential for X-ALD.

### 3. Genetic aspects of X-ALD

The *ABCD1* gene (GenBank accession number: NM\_000033) was identified by the use of positional cloning strategies [43]. The gene covers 19.9 kb, contains 10 exons and encodes a peroxisomal transmembrane protein of 745 amino acids with the general structure of an ATP-binding cassette (ABC) transporter [61]. All X-ALD patients have mutations within the *ABCD1* gene, which confirmed that this is the genetic cause of X-ALD. The disorder is inherited in an X-linked manner. Hence, if a female is a carrier for X-ALD, 50% of her daughters will be heterozygous carriers for X-ALD and 50% of her sons will have X-ALD. All daughters of an affected male will be carriers but none of his sons will be affected. Wang and coworkers reported that among 489 X-ALD families tested at the Kennedy Krieger Institute, 4.1% of the patients were affected by a *de novo* mutation in the index case, which indicates that the mutation occurred in the germ line [62]. Less than 1% had evidence of gonadal or gonosomal mosaicism. The residual maternal risk for having additional ovi carrying the mutant allele, however, is at least 13%. Thus, there remains significant reproductive risk for transmission of the disease-causing allele to other offspring [62].

#### 3.1. *ABCD1* pseudogenes and mutation analysis

As mentioned previously, approximately 20% of obligate heterozygotes have normal plasma VLCFA levels. Therefore, mutational analysis is required for accurate identification of women at risk to be heterozygous for *ABCD1* mutations and for effective mutational screening in affected families. However, special care must be taken for primer selection when the *ABCD1* gene is sequenced because interchromosomal duplications of exons 7–10 to chromosomes 2q11, 10p11, 16p11 and 22q11 have occurred due to pericentromeric plasticity [63]. Comparative sequence analysis showed that the pseudogenes share 92–96% nucleotide identity with the *ABCD1* gene. For conventional sequence analysis, *ABCD1* gene-specific primers have been designed [25]. It should be stressed that the high degree of sequence identity between the *ABCD1* locus and the pseudogenes may generate problems in “next-

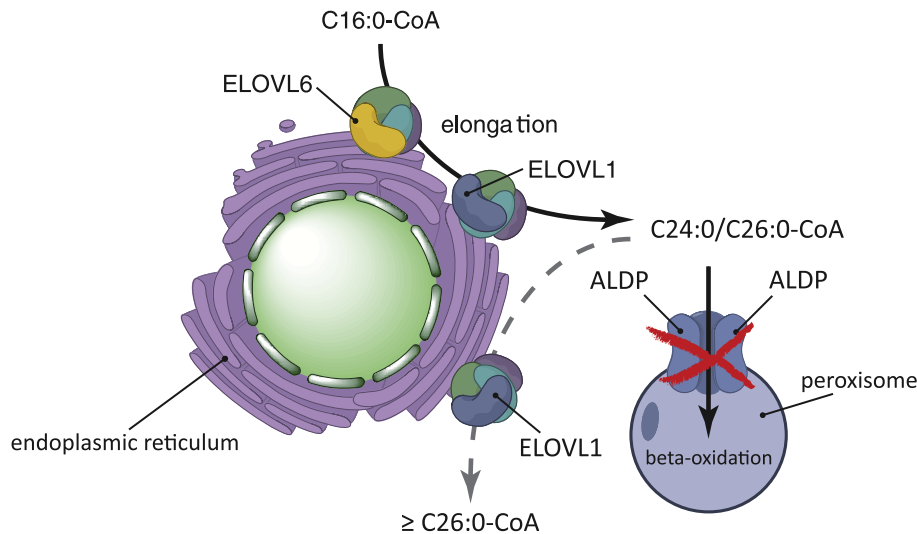
generation-sequencing” based on complications during sequence alignment of short fragments derived from the different autosomal pseudogenes and the *ABCD1* gene. Consequently, mutations in *ABCD1* might be overseen.

#### 3.2. The nature and frequency of *ABCD1* mutations

Based on mutational analysis of the *ABCD1* gene in X-ALD patients, 587 different mutations have been described up to now [64] (<http://www.x-ald.nl>). Of these mutations, 300 (51%) are missense mutations, 166 (28%) frame shift mutations, 68 (12%) nonsense mutations, 35 (6%) amino acid insertions/deletions and 18 (3%) larger deletions of one or more exons. It is described that 77% of all non-recurrent *ABCD1* mutations result in the absence of ALDP (<http://www.x-ald.nl>). This is, on the one hand, due to the fact that 50% of *ABCD1* mutations, such as nonsense and frame shift mutations as well as larger deletions lead to a truncated protein. On the other hand, many missense mutations result in unstable protein; here the absence of ALDP might be a question of sensitivity of detection. In most cases, the absence of detectable ALDP was judged by using anti-ALDP immunofluorescence microscopy in cultured fibroblasts from patients. However, fibroblasts express relatively low levels of *ABCD1* and thus, in some cases a partial reduction may lead to the complete disappearance of anti-ALDP immunofluorescence, while still being detectable by using the more sensitive western blot method. Indeed, Zhang and coworkers developed a method for accurate quantification of low amounts of ALDP and reinvestigated ALDP expression in cell lines that had been scored previously ALDP negative based on immunofluorescence [22]. This revealed that residual ALDP is detectable in all analyzed cell lines with a missense mutation, but the levels were often below the level of detection by immunofluorescence. Hence, ALDP could be detectable by immunohistochemistry when cell types with high *ABCD1* expression level are used. Disease-associated missense mutations are not equally distributed over the protein. Analysis of the distribution of the 300 missense mutations reveals that there are two regions in which the majority of missense mutations are found. The first region is located in the transmembrane domain region between amino acids 83 and 344 and the second is located in the ATP-binding domain between amino acids 500 and 668. The N-terminal 73 amino acids and the C-terminal 50 amino acids are mostly spared from missense mutations. Thus, caution is warranted when interpreting missense mutations in this region. The mutation p.Asn13Thr, for example, has been shown to represent a polymorphism, as this mutation did not affect the ability to compensate for the lack of functional ALDP after transfection [65].

#### 3.3. Genotype and phenotype in X-ALD

In other, non-peroxisomal ABC-transporters, like for example ABCB1 (Pgp/MDR1) or ABCA4 (ABCR), individual mutations can lead to residual transporter capacity and, as in the case of ABCA4, be associated with a later onset form of Stargardt disease [66]. There is no simple and general genotype–phenotype relation in X-ALD. Large deletions, nonsense mutations or frame shift mutations which result in the complete absence of a functional ALDP are found in patients covering the full spectrum of X-ALD phenotypes including very mild forms of late onset AMN. The best example for this is the most common *ABCD1* mutation, a deletion of two base-pairs resulting in a frame shift (p.Gln472fsX83) leading to a truncated ALDP that lacks the ATP-binding domain and is thus nonfunctional. This micro-deletion has been identified in 81 out of 1234 analyzed *ABCD1* genes and the affected patients presented with all different variants of X-ALD [67]. Another striking demonstration of the lack of a simple genotype–phenotype correlation is the presence of five different phenotypes in six male patients of a family with a destabilizing missense mutation, p.Pro484Arg [68]. These observations clearly demonstrate that the total lack of a functional ALDP



**Fig. 2.** Very long-chain fatty acids (VLCFA) are synthesized through elongation of long-chain fatty acids. VLCFA synthesis involves the elongases ELOVL6 (C18:0–C22:0) and ELOVL1 (C24:0–C26:0). ALDP transports C24:0/C26:0-CoA across the peroxisomal membrane. A deficiency in ALDP impairs peroxisomal VLCFA beta-oxidation but also raises cytosolic levels of C24:0/C26:0-CoA which are substrate for further elongation by ELOVL1 (adapted from [51]).

transporter alone does not necessarily lead to the severe form of X-ALD. Thus, additional factors are required to initiate the inflammatory process. Head trauma has been described as one of several possible “environmental” risk factors able to trigger the rapidly progressive inflammatory demyelination in AMN patients [69]. However, this does not exclude that some mutations with residual transporter activity might exclusively lead to AMN, irrespective of other factors. For example, a Dutch kindred has been described in which all heterozygous females are asymptomatic and all X-ALD males are either still asymptomatic at old age or show mild phenotypes including gonadal insufficiency and AMN without cerebral involvement [64]. The affected members of this kindred carry a missense mutation p.Arg389His that results in stable ALDP correctly localized to peroxisomes. This mutation may thus represent such a rare variant of a genotype–phenotype relation.

### 3.4. Genetic modifiers in X-ALD

Segregation analysis suggests that in addition to the disease causing *ABCD1* mutations and environmental factors, other genetic autosomal inherited factors are involved in the clinical manifestation of X-ALD [70,70,71]. The demonstration that ALDP-related protein (ALDRP, *ABCD2*), the closest homolog of ALDP, has an overlapping function with ALDP [72] suggested the *ABCD2* gene as a putative X-ALD modifier gene. However, sequence and segregation analyses of the *ABCD2* gene in a large X-ALD family with different phenotypes, as well as two independent association studies of polymorphisms and clinical phenotypes excluded *ABCD2* as a major modifier locus in X-ALD [73,74]. Investigations of other candidate genes such as the HLA haplotype have shown conflicting results [75,76], but these analyses may have been performed in underpowered sample collectives making a final conclusion uncertain. However, positive association studies with variants in genes involved in methionine metabolism [77,78], and *SOD2* [79], or altered gene expression of Bubblegum (a member of the VLCFA-acyl-CoA synthetase family) [34], and *ABCD4* (PMP69/P70R, another half ABC-transporter with high homology to ALDP) [34], might indicate their involvement in the pathology of X-ALD. Also, detailed investigations of the *CD1* gene cluster involving 23 carefully selected tag-SNPs within this gene region in 87 childhood cerebral ALD and 52 pure-AMN patients (defined as older than 45 years and without cerebral involvement)

identified one SNP, rs973742, located 4 kb downstream from the *CD1D* gene. The minor allele was significantly more frequent in pure-AMN patients ( $\chi^2 = 7.6$ ;  $P = 0.006$ ). However, this association was no longer statistically significant after Bonferroni correction for multiple testing [80]. This is a general problem associated with rare diseases in which the sample size is relatively small, but nevertheless it likely provides evidence for a possible involvement in the molecular mechanism of X-ALD. *ELOVL1* is another candidate modifier gene based on its important function in VLCFA synthesis [50]. Interestingly, a SNP has been identified in the promoter region of the *ELOVL1* (Kemp and Aubourg, unpublished observations). The functional effect of this SNP is under investigation. In summary, it seems unlikely that there is a single modifier locus that allows the prediction of the future phenotypic outcome for a presymptomatic X-ALD patient. The data currently available point to the existence of many rare genetic variant interactions that affect the clinical manifestations in X-ALD patients. This is the experience that is observed in many multifactorial diseases [81].

### 3.5. Prenatal diagnosis

Prenatal diagnosis to detect a possible affected male fetus can be offered to women whose heterozygous status has been clearly confirmed by genetic analysis of the *ABCD1* gene. In some countries, noninvasive prenatal determination of fetal sex using cell-free fetal DNA present in maternal blood may be performed at 7 weeks of pregnancy. It relies upon the detection of Y chromosome sequences by PCR techniques [82]. If the fetus is a male, *ABCD1* mutational analysis can be performed on a fresh chorionic villus sample (CVS) at 11–13 weeks of pregnancy. Alternatively, the determination of fetal sex can be performed by conventional cytogenetic techniques on a CVS sample at 11–13 weeks of pregnancy and then *ABCD1* mutational analysis performed if the fetus is a male. Mutation analysis takes a few days. Prenatal diagnosis can also be done on amniotic cells at 15–18 weeks of gestation. This approach, however, requires at least an additional 2–3 weeks of amniotic cell culture in order to generate enough cell material for molecular analysis. In case the *ABCD1* mutation has not yet been identified in the family, but the heterozygous status of the female has been clearly established biochemically by the demonstration of increased VLCFA levels in her plasma, prenatal diagnosis of a male fetus has to be done by the measurement of



VLCFA levels in cultured CVS cells or amniotic cells. Preimplantation genetic diagnosis can also be offered in some countries for selected cases. Usually this is done when a heterozygous female has had at least two prenatal diagnoses leading to pregnancy interruption because the fetus was an X-ALD male. A significant number of heterozygous women develop AMN in adulthood and prenatal diagnosis of a female fetus to establish whether the fetus has X-ALD may be offered on an individual basis. This situation occurs more and more frequently when either the father or the pregnant mother has severe AMN.

#### 4. Pathophysiology of X-ALD

##### 4.1. AMN

AMN, the most frequent phenotype of X-ALD, is nearly completely penetrant in adult males and affects 65% of heterozygous women by the age of 60 years (Engelen et al., manuscript in preparation). The *Abcd1* knockout mouse develops a phenotype that resembles AMN at 18–20 months of age, but no cerebral demyelination [40]. The neuropathological hallmark of AMN is an axonopathy with microgliosis but without significant myelin changes [83]. In the CNS, ALDP is mostly expressed in oligodendrocytes, microglia, astrocytes and endothelial cells [84], but not in most neurons with the exception of hypothalamus, basal nucleus of Meynert, periaqueductal gray matter and in the locus coeruleus [85]. A direct role for oligodendrocytes to sustain axonal function is supported by the observation that mice lacking 2',3'-cyclic nucleotide phosphodiesterase (CNPase) or proteolipid protein (PLP) display axonal dysfunction without demyelination in the spinal cord and brain [86,87]. It is therefore possible that the primary consequence of the loss of ALDP function in oligodendrocytes triggers progressive axonal damage without significant demyelination. Confirmation that this hypothesis is correct would require the targeted inactivation of the *Abcd1* gene specifically in mouse oligodendrocytes and follow up to evaluate whether these mice indeed develop the AMN-like phenotype. In X-ALD patients, this degenerative process, however, is very slow and takes decades to finally result in clinical symptoms of AMN. Interestingly, *Abcd1* knockout mice display oxidative damage to proteins in the spinal cord already at the age of 3 months [39], long before the first neuropathological lesions in the spinal cord at around 16 months of age and clinical signs at 20 months of age [40]. Loss of function of ALDP and possibly the accumulation of VLCFA result in oxidative stress in oligodendrocytes. This oxidative stress and/or antioxidant defense impairment in oligodendrocytes could be the major factor that initiates axonal damage in X-ALD. This notion is supported by the observation that antioxidants reduce markers for oxidative stress and axonal degeneration in the spinal cord of *Abcd1* knockout mice [88]. Yet, recent transcriptomic analysis highlighted other pathways that are dysregulated in *Abcd1* knockout mice, including oxidative phosphorylation, adipocytokine and insulin signaling pathways, protein synthesis and turnover, NF-kappa B mediated pro-inflammatory response, inflammatory response related to TGF beta, and the Toll-like receptor pathway [89]. Consistent with the microgliosis observed at the neuropathological level, these data suggest that a pro-inflammatory status is also present in AMN.

##### 4.2. Cerebral demyelination

Not all X-ALD males develop cerebral demyelination with severe neuroinflammation. Because of the absence of general genotype–phenotype correlation in X-ALD, it is likely that a combination of genetic, epigenetic and environmental factors play an essential role as triggers for the development of cerebral ALD. This is supported by the development of different clinical phenotypes in monozygotic twins [90,91] and the observation that moderate head trauma can initiate

cerebral demyelination in AMN patients [69]. Even though there is no correlation between the levels of VLCFA in plasma or fibroblasts and the X-ALD phenotype, VLCFA are highly elevated in myelin-specific lipid species [18,26–29]. These VLCFA-enriched complex lipids could be a key factor that contributes to the initiation of myelin instability and then cerebral demyelination. Indeed, VLCFA levels are higher in the normal appearing white matter of patients with cerebral ALD than in the normal white matter of AMN patients [34]. In line with this, oligodendrocytes derived from induced pluripotent stem cells from a patient with cerebral ALD accumulated more VLCFA than those derived from an AMN patient [92]. The synthesis of VLCFA (C26:0) is enhanced in X-ALD [56] and it requires the elongases ELOVL6 and ELOVL1 [50,51]. Genetic polymorphism in these elongases may affect the further elongation of C26:0 acyl-CoA esters into even longer fatty acids that would result in more sustained myelin sheath instability. It has been hypothesized that secondary peroxisomal dysfunction may contribute to cerebral demyelination and even neuroinflammation in X-ALD [93]. This hypothesis is based on the observation that mice lacking functional peroxisomes in oligodendrocytes initially show normal myelination, but develop axonal swelling followed by cerebral demyelination and infiltration of inflammatory T cells [94].

Plasmalogens are reduced in the brain lesions of cerebral ALD patients [95]. A decrease in plasmalogen levels could alter the transport of cholesterol which is an essential component of the myelin sheath [96], it could increase the oxidation of cholesterol in phospholipid bilayers [97] which in turn may result in cytotoxic, oxidative and inflammatory activities [98] and increased oxidative stress in glial cells [99].

As mentioned before, a pro-inflammatory status is present in *Abcd1* knockout mice that do not develop cerebral demyelination. Polymorphisms in genes involved in the different pathways that promote or counteract this pro-inflammatory stage may also play an important role in advancing or preventing the transition from a pro-inflammatory to a full-blown neuroinflammatory stage. The accumulation of T and B lymphocytes beyond the actively demyelinating lesions in the brain are strongly suggestive of an immune attack [100]. Candidate antigens include VLCFA-enriched complex lipids that are recognized by the CD1 molecules that play a major role in MHC-unrestricted lipid antigen presentation. The presence of these lipid antigens, does not exclude the participation of protein antigens as the cause of the immune attack in X-ALD.

It is also likely that microglia with normal ALDP function play a significant role in halting the initiation and progression of cerebral demyelination with neuroinflammation. This is strongly supported by the fact that both allogeneic hematopoietic stem cell (HSC) transplantation and autologous HSC gene therapy are very effective in arresting and even reversing neuroinflammatory cerebral ALD, provided that the procedure is performed at an early stage [101,102].

For the majority of X-ALD patients, including males and females with AMN, as well as males with too advanced cerebral demyelinating disease for allogeneic HSC transplantation to be effective, treatment options are very limited and mostly symptomatic [103]. Research targeted at understanding the pathophysiology observed in the X-ALD mouse has resulted in novel therapeutic strategies that could potentially halt or slow down the neuroinflammation process and/or axonal degeneration [104]. More basic research is however crucial to create a clear picture of the various pathophysiological aspects of X-ALD. In this respect, the absence of a relevant X-ALD mouse model that develops cerebral demyelination with neuroinflammation is a major limitation in deciphering the mechanism underlying the onset of cerebral inflammatory demyelination in X-ALD.

#### Acknowledgements

We thank Dr Sonja Forss-Petter and Dr Marc Engelen for critical comments on the manuscript. This work was supported by grants

from the Netherlands Organization for Scientific Research (91786328 to S.K.), the Vienna Science and Technology Fund (WWTF-project LS154 to J.B.), INSERM (to P.A.) and the European Union Framework Programme 7 (LEUKOTREAT 241622) (to S.K./J.B./P.A.).

## References

- [1] P. Aubourg, X-linked adrenoleukodystrophy, in: P.J. Vinken, C.W. Bruyn, H.W. Moser (Eds.), *Handbook of Clinical Neurology*, vol. 66, Elsevier, Amsterdam, 1996, pp. 447–483.
- [2] H.W. Moser, A. Mahmood, G.V. Raymond, X-linked adrenoleukodystrophy, *Nat. Clin. Pract. Neurol.* 3 (2007) 140–151.
- [3] B.M. van Geel, L. Bezman, D.J. Loes, H.W. Moser, G.V. Raymond, Evolution of phenotypes in adult male patients with X-linked adrenoleukodystrophy, *Ann. Neurol.* 49 (2001) 186–194.
- [4] V. Chaudhry, H.W. Moser, D.R. Cornblath, Nerve conduction studies in adrenomyeloneuropathy, *J. Neurol. Neurosurg. Psychiatry* 61 (1996) 181–185.
- [5] B.P. O'Neill, H.W. Moser, K.M. Saxena, L.C. Marmion, Adrenoleukodystrophy: clinical and biochemical manifestations in carriers, *Neurology* 34 (1984) 798–801.
- [6] C. Teritehau, C. Adamsbaum, V. Merzoug, G. Kalifa, A. Tourbah, P. Aubourg, Subtle brain abnormalities in adrenomyeloneuropathy, *J. Radiol.* 88 (2007) 957–961.
- [7] E. Ratai, T. Kok, C. Wiggins, G. Wiggins, E. Grant, B. Gagoski, G. O'Neill, E. Adalsteinsson, F. Eichler, Seven-Tesla proton magnetic resonance spectroscopic imaging in adult X-linked adrenoleukodystrophy, *Arch. Neurol.* 65 (2008) 1488–1494.
- [8] P. Dubey, A. Fatemi, H. Huang, L. Nagae-Poetscher, S. Wakana, P.B. Barker, Z.P. van, H.W. Moser, S. Mori, G.V. Raymond, Diffusion tensor-based imaging reveals occult abnormalities in adrenomyeloneuropathy, *Ann. Neurol.* 58 (2005) 758–766.
- [9] A. Fatemi, S.A. Smith, P. Dubey, K.M. Zackowski, A.J. Bastian, P.C. van Zijl, H.W. Moser, G.V. Raymond, X. Golay, Magnetization transfer MRI demonstrates spinal cord abnormalities in adrenomyeloneuropathy, *Neurology* 64 (2005) 1739–1745.
- [10] S.A. Smith, X. Golay, A. Fatemi, A. Mahmood, G.V. Raymond, H.W. Moser, P.C. van Zijl, G.J. Stanisz, Quantitative magnetization transfer characteristics of the human cervical spinal cord *in vivo*: application to adrenomyeloneuropathy, *Magn. Reson. Med.* 61 (2009) 22–27.
- [11] H. Matsumoto, R. Hanajima, Y. Terao, M. Hamada, A. Yugeta, Y. Shirota, K. Yuasa, F. Sato, T. Matsukawa, Y. Takahashi, J. Goto, S. Tsuji, Y. Ugawa, Efferent and afferent evoked potentials in patients with adrenomyeloneuropathy, *Clin. Neurol. Neurosurg.* 112 (2010) 131–136.
- [12] D.J. Loes, S. Hite, H. Moser, A.E. Stillman, E. Shapiro, L. Lockman, R.E. Latchaw, W. Krivit, Adrenoleukodystrophy: a scoring method for brain MR observations, *AJNR Am. J. Neuroradiol.* 15 (1994) 1761–1766.
- [13] E.R. Melhem, P.B. Barker, G.V. Raymond, H.W. Moser, X-linked adrenoleukodystrophy in children: review of genetic, clinical, and MR imaging characteristics, *AJR Am. J. Roentgenol.* 173 (1999) 1575–1581.
- [14] H.W. Moser, K.D. Smith, P.A. Watkins, J. Powers, A.B. Moser, X-linked adrenoleukodystrophy, in: C.R. Scriver, A.L. Beaudet, W.S. Sly, D. Valle (Eds.), *The Metabolic and Molecular Bases of Inherited Disease*, McGraw Hill, New York, 2001, pp. 3257–3301.
- [15] C.C. Forsyth, M. Forbes, J.N. Cumings, Adrenocortical atrophy and diffuse cerebral sclerosis, *Arch. Dis. Child.* 46 (1971) 273–284.
- [16] J.M. Powers, H.H. Schaumburg, Adreno-leukodystrophy (sex-linked Schilder's disease). A pathogenetic hypothesis based on ultrastructural lesions in adrenal cortex, peripheral nerve and testis, *Am. J. Pathol.* 76 (1974) 481–491.
- [17] A.B. Johnson, H.H. Schaumburg, J.M. Powers, Histochemical characteristics of the striated inclusions of adrenoleukodystrophy, *J. Histochem. Cytochem.* 24 (1976) 725–730.
- [18] M. Igarashi, H.H. Schaumburg, J. Powers, Y. Kishimoto, E. Kolodny, K. Suzuki, Fatty acid abnormality in adrenoleukodystrophy, *J. Neurochem.* 26 (1976) 851–860.
- [19] I. Singh, H.W. Moser, A.B. Moser, Y. Kishimoto, Adrenoleukodystrophy: impaired oxidation of long chain fatty acids in cultured skin fibroblasts an adrenal cortex, *Biochem. Biophys. Res. Commun.* 102 (1981) 1223–1229.
- [20] H. Osmundsen, Peroxisomal beta-oxidation of long fatty acids: effects of high fat diets, *Ann. N. Y. Acad. Sci.* 386 (1982) 13–29.
- [21] I. Singh, A.E. Moser, S. Goldfischer, H.W. Moser, Lignoceric acid is oxidized in the peroxisome: implications for the Zellweger cerebro-hepato-renal syndrome and adrenoleukodystrophy, *Proc. Natl. Acad. Sci. U. S. A.* 81 (1984) 4203–4207.
- [22] X. Zhang, L.C. De Marcos, N. Schutte-Lensink, R. Ofman, R.J. Wanders, S.A. Baldwin, A. Baker, S. Kemp, F.L. Theodoulou, Conservation of targeting but divergence in function and quality control of peroxisomal ABC transporters: an analysis using cross-kingdom expression, *Biochem. J.* 436 (2011) 547–557.
- [23] S. Kemp, F. Valianpour, P.A. Mooyer, W. Kulik, R.J. Wanders, Method for measurement of peroxisomal very-long-chain fatty acid [beta]-oxidation in human skin fibroblasts using stable-isotope-labeled tetracosanoic acid, *Clin. Chem.* 50 (2004) 1824–1826.
- [24] H.W. Moser, A.B. Moser, K.K. Frayer, W. Chen, J.D. Schulman, B.P. O'Neill, Y. Kishimoto, Adrenoleukodystrophy: increased plasma content of saturated very long chain fatty acids, *Neurology* 31 (1981) 1241–1249.
- [25] C.D. Boehm, G.R. Cutting, M.B. Lachtermacher, H.W. Moser, S.S. Chong, Accurate DNA-based diagnostic and carrier testing for X-linked adrenoleukodystrophy, *Mol. Genet. Metab.* 66 (1999) 128–136.
- [26] M. Garashi, D. Belchis, K. Suzuki, Brain gangliosides in adrenoleukodystrophy, *J. Neurochem.* 27 (1976) 327–328.
- [27] O.A. Bizzozero, G. Zuniga, M.B. Lees, Fatty acid composition of human myelin proteolipid protein in peroxisomal disorders, *J. Neurochem.* 56 (1991) 872–878.
- [28] C. Theda, A.B. Moser, J.M. Powers, H.W. Moser, Phospholipids in X-linked adrenoleukodystrophy white matter: fatty acid abnormalities before the onset of demyelination, *J. Neurol. Sci.* 110 (1992) 195–204.
- [29] R. Wilson, J.R. Sargent, Lipid and fatty acid composition of brain tissue from adrenoleukodystrophy patients, *J. Neurochem.* 61 (1993) 290–297.
- [30] O.A. Bizzozero, L.K. Good, J.E. Evans, Cysteine-108 is an acylation site in myelin proteolipid protein, *Biochem. Biophys. Res. Commun.* 170 (1990) 375–382.
- [31] W.C. Hubbard, A.B. Moser, S. Tortorelli, A. Liu, D. Jones, H. Moser, Combined liquid chromatography-tandem mass spectrometry as an analytical method for high throughput screening for X-linked adrenoleukodystrophy and other peroxisomal disorders: preliminary findings, *Mol. Genet. Metab.* 89 (2006) 185–187.
- [32] W.C. Hubbard, A.B. Moser, A.C. Liu, R.O. Jones, S.J. Steinberg, F. Lorey, S.R. Panny, R.F. Vogt Jr., D. Macaya, C.T. Turgeon, S. Tortorelli, G.V. Raymond, Newborn screening for X-linked adrenoleukodystrophy (X-ALD): validation of a combined liquid chromatography-tandem mass spectrometric (LC-MS/MS) method, *Mol. Genet. Metab.* 97 (2009) 212–220.
- [33] C.J. Reinecke, D.P. Knoll, P.J. Pretorius, H.S. Steyn, R.H. Simpson, The correlation between biochemical and histopathological findings in adrenoleukodystrophy, *J. Neurol. Sci.* 70 (1985) 21–38.
- [34] M. Asheuer, I. Bieche, I. Laurendeau, A. Moser, B. Hainque, M. Vidaud, P. Aubourg, Decreased expression of ABCD4 and BG1 genes early in the pathogenesis of X-linked adrenoleukodystrophy, *Hum. Mol. Genet.* 14 (2005) 1293–1303.
- [35] J.K. Ho, H. Moser, Y. Kishimoto, J.A. Hamilton, Interactions of a very long chain fatty acid with model membranes and serum albumin. Implications for the pathogenesis of adrenoleukodystrophy, *J. Clin. Invest.* 96 (1995) 1455–1463.
- [36] R.A. Knazek, W.B. Rizzo, J.D. Schulman, J.R. Dave, Membrane microviscosity is increased in the erythrocytes of patients with adrenoleukodystrophy and adrenomyeloneuropathy, *J. Clin. Invest.* 72 (1983) 245–248.
- [37] R.W. Whitcomb, W.M. Linehan, R.A. Knazek, Effects of long-chain, saturated fatty acids on membrane microviscosity and adrenocorticotropin responsiveness of human adrenocortical cells *in vitro*, *J. Clin. Invest.* 81 (1988) 185–188.
- [38] S. Hein, P. Schonfeld, S. Kahlert, G. Reiser, Toxic effects of X-linked adrenoleukodystrophy-associated, very long chain fatty acids on glial cells and neurons from rat hippocampus in culture, *Hum. Mol. Genet.* 17 (2008) 1750–1761.
- [39] S. Fourcade, J. Lopez-Erasquin, J. Galino, C. Duval, A. Naudi, M. Jove, S. Kemp, F. Villarroya, I. Ferrer, R. Pamplona, M. Portero-Otin, A. Pujol, Early oxidative damage underlying neurodegeneration in X-adrenoleukodystrophy, *Hum. Mol. Genet.* 17 (2008) 1762–1773.
- [40] A. Pujol, C. Hindelang, N. Callizot, U. Bartsch, M. Schachner, J.L. Mandel, Late onset neurological phenotype of the X-ALD gene inactivation in mice: a mouse model for adrenomyeloneuropathy, *Hum. Mol. Genet.* 11 (2002) 499–505.
- [41] F.S. Eichler, J.Q. Ren, M. Cossoy, A.M. Rietsch, S. Nagpal, A.B. Moser, M.P. Frosch, R.M. Ransohoff, Is microglial apoptosis an early pathogenic change in cerebral X-linked adrenoleukodystrophy? *Ann. Neurol.* 63 (2008) 729–742.
- [42] M. Hashmi, W. Stanley, I. Singh, Lignoceryl-CoASH ligase: enzyme defect in fatty acid beta-oxidation system in X-linked childhood adrenoleukodystrophy, *FEBS Lett.* 196 (1986) 247–250.
- [43] J. Mosser, A.M. Douar, C.O. Sarde, P. Kioschis, R. Feil, H. Moser, A.M. Poustka, J.L. Mandel, P. Aubourg, Putative X-linked adrenoleukodystrophy gene shares unexpected homology with ABC transporters, *Nature* 361 (1993) 726–730.
- [44] Z. Jia, C.L. Moulson, Z. Pei, J.H. Miner, P.A. Watkins, Fatty acid transport protein 4 is the principal very long chain fatty acyl-CoA synthetase in skin fibroblasts, *J. Biol. Chem.* 282 (2007) 20573–20583.
- [45] N. Shinnoh, T. Yamada, T. Yoshimura, H. Furuya, Y. Yoshida, Y. Suzuki, N. Shimozawa, T. Orii, T. Kobayashi, Adrenoleukodystrophy: the restoration of peroxisomal beta-oxidation by transfection of normal cDNA, *Biochem. Biophys. Res. Commun.* 210 (1995) 830–836.
- [46] N. Cartier, J. Lopez, P. Moullet, F. Rocchiccioli, M.O. Rolland, P. Jorge, J. Mosser, J.L. Mandel, P.F. Bougneres, O. Danos, P. Aubourg, Retroviral-mediated gene transfer corrects very-long-chain fatty acid metabolism in adrenoleukodystrophy fibroblasts, *Proc. Natl. Acad. Sci. U. S. A.* 92 (1995) 1674–1678.
- [47] E.H. Hettema, C.W. van Roermund, B. Distel, M. van Den Berg, C. Vilela, C. Rodrigues-Pousada, R.J. Wanders, H.F. Tabak, The ABC transporter proteins Pat1 and Pat2 are required for import of long-chain fatty acids into peroxisomes of *Saccharomyces cerevisiae*, *EMBO J.* 15 (1996) 3813–3822.
- [48] N. Verleue, E.H. Hettema, C.W. van Roermund, H.F. Tabak, R.J. Wanders, Transport of activated fatty acids by the peroxisomal ATP-binding-cassette transporter Pxa2 in a semi-intact yeast cell system, *Eur. J. Biochem.* 249 (1997) 657–661.
- [49] C.W.T. van Roermund, W.F. Visser, L. IJlst, A. van Cruchten, M. Boek, W. Kulik, H.R. Waterham, R.J.A. Wanders, The human peroxisomal ABC half transporter ALDP functions as a homodimer and accepts acyl-CoA esters, *FASEB J.* 22 (2008) 4201–4208.
- [50] R. Ofman, I.M. Dijkstra, C.W. van Roermund, N. Burger, M. Turkenburg, A. van Cruchten, C.E. van Engen, R.J. Wanders, S. Kemp, The role of ELOVL1 in very long-chain fatty acid homeostasis and X-linked adrenoleukodystrophy, *EMBO Mol. Med.* 2 (2010) 90–97.



- [51] S. Kemp, R. Wanders, Biochemical aspects of X-linked adrenoleukodystrophy, *Brain Pathol.* 20 (2010) 831–837.
- [52] Y. Kishimoto, H.W. Moser, N. Kawamura, M. Platt, S.L. Pallante, C. Fenselau, Adrenoleukodystrophy: evidence that abnormal very long chain fatty acids of brain cholesterol esters are of exogenous origin, *Biochem. Biophys. Res. Commun.* 96 (1980) 69–76.
- [53] S. Tsuji, T. Sano, T. Ariga, T. Miyatake, Increased synthesis of hexacosanoic acid (C26:0) by cultured skin fibroblasts from patients with adrenoleukodystrophy (ALD) and adrenomyeloneuropathy (AMN), *J. Biochem.* 90 (1981) 1233–1236 (Tokyo).
- [54] W.B. Rizzo, J. Avigan, J. Chemke, J.D. Schulman, Adrenoleukodystrophy: very long-chain fatty acid metabolism in fibroblasts, *Neurology* 34 (1984) 163–169.
- [55] F.R. Brown, M.A. Van Duyn, A.B. Moser, J.D. Schulman, W.B. Rizzo, R.D. Snyder, J.V. Murphy, S. Kamoshita, C.J. Migeon, H.W. Moser, Adrenoleukodystrophy: effects of dietary restriction of very long chain fatty acids and of administration of carnitine and clofibrate on clinical status and plasma fatty acids, *Johns. Hopkins. Med. J.* 151 (1982) 164–172.
- [56] S. Kemp, F. Valianpour, S. Denis, R. Ofman, R.J. Sanders, P. Mooyer, P.G. Barth, R.J.A. Wanders, Elongation of very long-chain fatty acids is enhanced in X-linked adrenoleukodystrophy, *Mol. Genet. Metab.* 84 (2005) 144–151.
- [57] S.J. Wakil, Fatty acid synthase, a proficient multifunctional enzyme, *Biochemistry* 28 (1989) 4523–4530.
- [58] P. Osei, S.K. Suneja, J.C. Laguna, M.N. Nagi, L. Cook, M.R. Prasad, D.L. Cinti, Topography of rat hepatic microsomal enzymatic components of the fatty acid chain elongation system, *J. Biol. Chem.* 264 (1989) 6844–6849.
- [59] D.L. Cinti, L. Cook, M.N. Nagi, S.K. Suneja, The fatty acid chain elongation system of mammalian endoplasmic reticulum, *Prog. Lipid Res.* 31 (1992) 1–51.
- [60] A. Jakobsson, R. Westerberg, A. Jakobsson, Fatty acid elongases in mammals: their regulation and roles in metabolism, *Prog. Lipid Res.* 45 (2006) 237–249.
- [61] S. Kemp, F.L. Theodoulou, R.J. Wanders, Mammalian peroxisomal ABC transporters: from endogenous substrates to pathology and clinical significance, *Br. J. Pharmacol.* 164 (2011) 1753–1766.
- [62] Y. Wang, R. Busin, C. Reeves, L. Bezman, G. Raymond, C.J. Toomer, P.A. Watkins, A. Snowden, A. Moser, S. Naidu, G. Bibat, S. Hewson, K. Tam, J.T. Clarke, L. Charnas, G. Stetten, B. Karczeski, G. Cutting, S. Steinberg, X-linked adrenoleukodystrophy: ABCD1 *de novo* mutations and mosaicism, *Mol. Genet. Metab.* 104 (2011) 160–166.
- [63] E.E. Eichler, M.L. Budarf, M. Rocchi, L.L. Deaven, N.A. Doggett, A. Baldini, D.L. Nelson, H.W. Mohrenweiser, Interchromosomal duplications of the adrenoleukodystrophy locus: a phenomenon of pericentromeric plasticity, *Hum. Mol. Genet.* 6 (1997) 991–1002.
- [64] S. Kemp, A. Pujol, H.R. Waterham, B.M. van Geel, C.D. Boehm, G.V. Raymond, G.R. Cutting, R.J. Wanders, H.W. Moser, ABCD1 mutations and the X-linked adrenoleukodystrophy mutation database: role in diagnosis and clinical correlations, *Hum. Mutat.* 18 (2001) 499–515.
- [65] L. Dvorakova, G. Storkanova, G. Unterrainer, J. Hujova, S. Kmoch, J. Zeman, M. Hrebicek, J. Berger, Eight novel ABCD1 gene mutations and three polymorphisms in patients with X-linked adrenoleukodystrophy: the first polymorphism causing an amino acid exchange, *Hum. Mutat.* 18 (2001) 52–60.
- [66] A.N. Yatsenko, N.F. Shroyer, R.A. Lewis, J.R. Lupski, Late-onset Stargardt disease is associated with missense mutations that map outside known functional regions of ABCR (ABCA4), *Hum. Genet.* 108 (2001) 346–355.
- [67] K.D. Smith, S. Kemp, L.T. Braiterman, J.F. Lu, H.M. Wei, M. Geraghty, G. Stetten, J.S. Bergin, J. Pevsner, P.A. Watkins, X-linked adrenoleukodystrophy: genes, mutations, and phenotypes, *Neurochem. Res.* 24 (1999) 521–535.
- [68] J. Berger, B. Molzer, I. Fae, H. Bernheimer, X-linked adrenoleukodystrophy (ALD): a novel mutation of the ALD gene in 6 members of a family presenting with 5 different phenotypes, *Biochem. Biophys. Res. Commun.* 205 (1994) 1638–1643.
- [69] G.V. Raymond, R. Seidman, T.S. Monteith, E. Kolodny, S. Sathe, A. Mahmood, J.M. Powers, Head trauma can initiate the onset of adreno-leukodystrophy, *J. Neurol. Sci.* 290 (2010) 70–74.
- [70] K.D. Smith, G. Sack, T.H. Beaty, A. Bergin, S. Naidu, A. Moser, H.W. Moser, A genetic basis for the multiple phenotypes of X-linked adrenoleukodystrophy, *Am. J. Hum. Genet.* 49 (1991) 165.
- [71] N.E. Maestri, T.H. Beaty, Predictions of a 2-locus model for disease heterogeneity: application to adrenoleukodystrophy, *Am. J. Med. Genet.* 44 (1992) 576–582.
- [72] A. Netik, S. Forss-Petter, A. Holzinger, B. Molzer, G. Unterrainer, J. Berger, Adrenoleukodystrophy-related protein can compensate functionally for adrenoleukodystrophy protein deficiency (X-ALD): implications for therapy, *Hum. Mol. Genet.* 8 (1999) 907–913.
- [73] E.M. Maier, P.U. Mayerhofer, M. Asheuer, W. Kohler, M. Rothe, A.C. Muntau, A.A. Roscher, A. Holzinger, P. Aubourg, J. Berger, X-linked adrenoleukodystrophy phenotype is independent of ABCD2 genotype, *Biochem. Biophys. Res. Commun.* 377 (2008) 176–180.
- [74] T. Matsukawa, M. Asheuer, Y. Takahashi, J. Goto, Y. Suzuki, N. Shimozawa, H. Takano, O. Onodera, M. Nishizawa, P. Aubourg, S. Tsuji, Identification of novel SNPs of ABCD1, ABCD2, ABCD3 and ABCD4 genes in patients with X-linked adrenoleukodystrophy (ALD) based on comprehensive resequencing and association studies with ALD phenotypes, *Neurogenetics* 12 (2011) 41–50.
- [75] J. Berger, H. Bernheimer, I. Fae, A. Braun, A. Roscher, B. Molzer, G. Fischer, Association of X-linked adrenoleukodystrophy with HLA DRB1 alleles, *Biochem. Biophys. Res. Commun.* 216 (1995) 447–451.
- [76] M.C. McGuinness, J.M. Powers, W.B. Bias, B.J. Schmeckpeper, A.H. Segal, V.C. Gowda, S.L. Wesselingh, J. Berger, D.E. Griffin, K.D. Smith, Human leukocyte antigens and cytokine expression in cerebral inflammatory demyelinating lesions of X-linked adrenoleukodystrophy and multiple sclerosis, *J. Neuroimmunol.* 75 (1997) 174–182.
- [77] M. Linnebank, S. Kemp, R.J.A. Wanders, W.J. Kleijer, M.L.T. van der Sterre, J. Gartner, K. Fliessbach, A. Semmler, P. Sokolowski, W. Kohler, U. Schlegel, S. Schmidt, T. Klockgether, U. Wullner, Methionine metabolism and phenotypic variability in X-linked adrenoleukodystrophy, *Neurology* 66 (2006) 442–443.
- [78] A. Semmler, X. Bao, G. Cao, W. Kohler, M. Weller, P. Aubourg, M. Linnebank, Genetic variants of methionine metabolism and X-ALD phenotype generation: results of a new study sample, *J. Neurol.* 256 (2009) 1277–1280.
- [79] R.D. Brose, D. Avramopoulos, K.D. Smith, SOD2 as a potential modifier of X-linked adrenoleukodystrophy clinical phenotypes, *J. Neurol.* (2012), doi:10.1007/s00415-011-6371-6378.
- [80] M. Barbier, A. Sabbagh, E. Kasper, M. Asheuer, O. Ahouansou, I. Pribill, S. Forss-Petter, M. Vidau, J. Berger, P. Aubourg, CD1 gene polymorphisms and phenotypic variability in X-linked adrenoleukodystrophy, *PLoS One* 7 (2012) e29872.
- [81] W. Bodmer, C. Bonilla, Common and rare variants in multifactorial susceptibility to common diseases, *Nat. Genet.* 40 (2008) 695–701.
- [82] S.A. Devaney, G.E. Palomaki, J.A. Scott, D.W. Bianchi, Noninvasive fetal sex determination using cell-free fetal DNA: a systematic review and meta-analysis, *JAMA* 306 (2011) 627–636.
- [83] J.M. Powers, D.P. DeCiero, M. Ito, A.B. Moser, H.W. Moser, Adrenomyeloneuropathy: a neuropathologic review featuring its noninflammatory myelopathy, *J. Neuropathol. Exp. Neurol.* 59 (2000) 89–102.
- [84] F. Fouquet, J.M. Zhou, E. Ralston, K. Murray, F. Troalen, E. Magal, O. Robain, M. Dubois-Dalq, P. Aubourg, Expression of the adrenoleukodystrophy protein in the human and mouse central nervous system, *Neurobiol. Dis.* 3 (1997) 271–285.
- [85] R. Hofberger, M. Kunze, I. Weinhofer, F. Boul-Enein, T. Voigtlander, I. Oezen, G. Amann, H. Bernheimer, H. Budka, J. Berger, Distribution and cellular localization of adrenoleukodystrophy protein in human tissues: implications for X-linked adrenoleukodystrophy, *Neurobiol. Dis.* 28 (2007) 165–174.
- [86] I. Griffiths, M. Klugmann, T. Anderson, D. Yool, C. Thomson, M.H. Schwab, A. Schneider, F. Zimmermann, M. McCulloch, N. Nadon, K.A. Nave, Axonal swellings and degeneration in mice lacking the major proteolipid of myelin, *Science* 280 (1998) 1610–1613.
- [87] C. Lappe-Siefke, S. Goebbels, M. Gravel, E. Nicksch, J. Lee, P.E. Braun, I.R. Griffiths, K.A. Nave, Disruption of Cnp1 uncouples oligodendroglial functions in axonal support and myelination, *Nat. Genet.* 33 (2003) 366–374.
- [88] J. Lopez-Erauskin, S. Fourcade, J. Galino, M. Ruiz, A. Schluter, A. Naudi, M. Jove, M. Portero-Otin, R. Pamplona, I. Ferrer, A. Pujol, Antioxidants halt axonal degeneration in a mouse model of X-adrenoleukodystrophy, *Ann. Neurol.* 70 (2011) 84–92.
- [89] A. Schluter, L. Espinosa, S. Fourcade, J. Galino, E. Lopez, E. Ilieva, L. Morato, M. Asheuer, T. Cook, A. McLaren, J. Reid, F. Kelly, S. Bates, P. Aubourg, E. Galea, A. Pujol, Functional genomic analysis unravels a metabolic-inflammatory interplay in adrenoleukodystrophy, *Hum. Mol. Genet.* 21 (2012) 1062–1077.
- [90] M. Di Rocco, L. Doria-Lamba, U. Caruso, Monozygotic twins with X-linked adrenoleukodystrophy and different phenotypes, *Ann. Neurol.* 50 (2001) 424.
- [91] G.C. Korenke, S. Fuchs, E. Krasemann, H.G. Doerr, E. Wilichowski, D.H. Hunneman, F. Hanefeld, Cerebral adrenoleukodystrophy (ALD) in only one of monozygotic twins with an identical ALD genotype, *Ann. Neurol.* 40 (1996) 254–257.
- [92] J. Jang, H.C. Kang, H.S. Kim, J.Y. Kim, Y.J. Huh, D.S. Kim, J.E. Yoo, J.A. Lee, B. Lim, J. Lee, T.M. Yoon, I.H. Park, D.Y. Hwang, G.Q. Daley, D.W. Kim, Induced pluripotent stem cell models from X-linked adrenoleukodystrophy patients, *Ann. Neurol.* 70 (2011) 402–409.
- [93] C.M. Kassmann, K.A. Nave, Oligodendroglial impact on axonal function and survival – a hypothesis, *Curr. Opin. Neurol.* 21 (2008) 235–241.
- [94] C.M. Kassmann, C. Lappe-Siefke, M. Baes, B. Brugger, A. Mildner, H.B. Werner, O. Natt, T. Michaelis, M. Prinz, J. Frahm, K.A. Nave, Axonal loss and neuroinflammation caused by peroxisome-deficient oligodendrocytes, *Nat. Genet.* 39 (2007) 969–976.
- [95] M. Khan, J. Singh, I. Singh, Plasmalogen deficiency in cerebral adrenoleukodystrophy and its modulation by lovastatin, *J. Neurochem.* 106 (2008) 1766–1779.
- [96] N.J. Munn, E. Arnio, D. Liu, R.A. Zoeller, L. Liscum, Deficiency in ethanolamine plasmalogen leads to altered cholesterol transport, *J. Lipid Res.* 44 (2003) 182–192.
- [97] R. Maeba, N. Ueta, Ethanolamine plasmalogens prevent the oxidation of cholesterol by reducing the oxidizability of cholesterol in phospholipid bilayers, *J. Lipid Res.* 44 (2003) 164–171.
- [98] A. Vejux, G. Lizard, Cytotoxic effects of oxysterols associated with human diseases: induction of cell death (apoptosis and/or oncosis), oxidative and inflammatory activities, and phospholipidosis, *Mol. Aspects Med.* 30 (2009) 153–170.
- [99] P. Brites, H.R. Waterham, R.J. Wanders, Functions and biosynthesis of plasmalogens in health and disease, *Biochim. Biophys. Acta* 1636 (2004) 219–231.
- [100] J.M. Powers, Y. Liu, A.B. Moser, H.W. Moser, The inflammatory myelinopathy of adreno-leukodystrophy: cells, effector molecules, and pathogenic implications, *J. Neuropathol. Exp. Neurol.* 51 (1992) 630–643.
- [101] W.P. Miller, S.M. Rothman, D. Nascene, T. Kivisto, T.E. DeFor, R.S. Ziegler, J. Eisengart, K. Leiser, G. Raymond, T.C. Lund, J. Tolar, P.J. Orchard, Outcomes after allogeneic hematopoietic cell transplantation for childhood cerebral adrenoleukodystrophy: the largest single-institution cohort report, *Blood* 118 (2011) 1971–1978.
- [102] N. Cartier, S. Hacein-Bey-Abina, C.C. Bartholomae, G. Veres, M. Schmidt, I. Kutschera, M. Vidau, U. Abel, L. Dal-Cortivo, L. Caccavelli, N. Mahloui, V. Kiermer, D. Mittelstaedt, C. Bellesme, N. Lahlou, F. Lefrere, S. Blanche, M. Audit, E. Payen, P. Leboulch, B. L'Homme, P. Bougneres, K.C. Von, A. Fischer, M.

Cavazzana-Calvo, P. Aubourg, Hematopoietic stem cell gene therapy with a lentiviral vector in X-linked adrenoleukodystrophy, *Science* 326 (2009) 818–823.

- [103] J. Berger, A. Pujol, P. Aubourg, S. Forss-Petter, Current and future pharmacological treatment strategies in X-linked adrenoleukodystrophy, *Brain Pathol.* 20 (2010) 845–856.
- [104] J. Galino, M. Ruiz, S. Fourcade, A. Schluter, J. Lopez-Erauskin, C. Guilera, M. Jove, A. Naudi, E. Garcia-Arumi, A.L. Andreu, A.A. Starkov, R. Pamplona, I. Ferrer, M. Portero-Otin, A. Pujol, Oxidative damage compromises energy metabolism in the axonal degeneration mouse model of X-adrenoleukodystrophy, *Antioxid. Redox. Signal.* 15 (2011) 2095–2107.